

AIS PennHIP

Owner's Copy

PennHIP Report

Referring Veterinarian: Dr William Patterson
 Email: PattersonVeterinary@gmail.com

Clinic Name: Patterson Animal Hospital
 Clinic Address: 35115 Harper
 Clinton Township, MI
 48035
 Phone: (586) 791-6260
 Fax: (586) 791-1368

Patient Information

Client: Grote, Gina
 Patient Name: Ivanka
 Reg. Name: Clinton Oaks Ivanka
 PennHIP Num: 123883
 Species: Canine
 Date of Birth: 24 Apr 2017
 Sex: Female
 Date of Study: 07 Nov 2018
 Date of Report: 11 Nov 2018

Tattoo Num:
 Patient ID: 30844-0005
 Registration Num: S500162006
 Microchip Num: 95600000992750
 Breed: GOLDEN RETRIEVER
 Age: 19 months
 Weight: 62 lbs/28.1 kgs
 Date Submitted: 07 Nov 2018

Findings

Distraction Index (DI): Right DI = 0.64, Left DI = 0.61.

Osteoarthritis (OA):

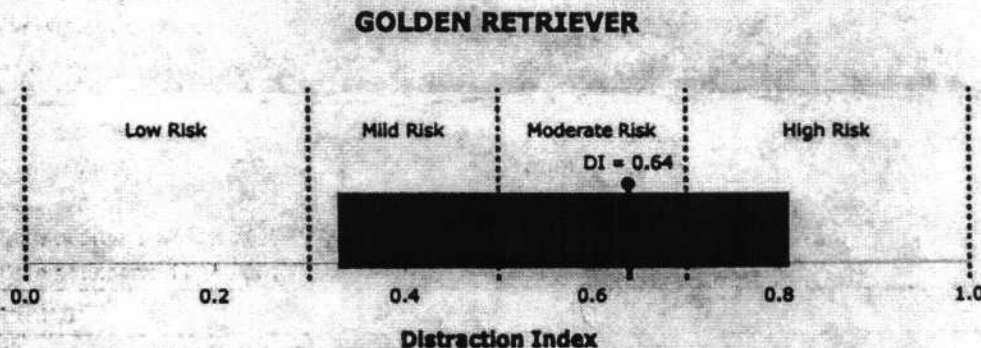
Cavitation/Other Findings: No cavitation present.

Interpretation

Distraction Index (DI): The laxity ranking is based on the hip with the greater laxity (larger DI). In this case the DI used is 0.64.

OA Risk Category: The DI is between 0.50 and 0.69. This patient is at moderate risk for hip OA.

Distraction Index Chart:



BREED STATISTICS: This interpretation is based on a cross-section of 19400 canine patients of the GOLDEN RETRIEVER breed in the AIS PennHIP database. The gray strip represents the central 90% range of DIs (0.33 - 0.81) for the breed. The breed average DI is 0.54 (solid square). The patient DI is the solid circle (0.64).

SUMMARY: The degree of laxity (DI = 0.64) falls within the central 90% range of DIs for the breed. This amount of hip